

## Tomographic Evaluation of the Position and Form of the Mental Foramen in a Brazilian Subpopulation

Débora Laís Ribeiro e Ribeiro Lacerda<sup>1</sup>, Patricia Costa Oliveira<sup>1</sup>, Camila Almeida de Andrade<sup>2</sup>, Caio Cesar Souza<sup>3</sup>, Gladyvam Rabelo Braitt<sup>3</sup>, Fábio Silveira de Souza<sup>4</sup>, Yanessa Santos Muniz<sup>5</sup>, Danielle Maia<sup>5</sup>, Ana Grasiela da Silva Limoeiro<sup>5</sup>, Antônio Henrique Braitt<sup>5</sup>, Milena Bortolotto Felipe Silva<sup>6</sup>

<sup>1</sup>Department of Radiology, School of Dentistry, Ilhéus University, Ilhéus, BA, Brazil

<sup>2</sup>Department of Endodontics, IBPO, Teixeira de Freitas, BA, Brazil

<sup>3</sup>Private Office

<sup>4</sup>Department of Orthodontics, School of Dentistry, Ilhéus University, Ilhéus, BA, Brazil

<sup>5</sup>Department of Endodontics, School of Dentistry, Ilhéus University, Ilhéus, BA, Brazil

<sup>6</sup>Department of Radiology, Dental Research Center, São Leopoldo Mandic University, Campinas, SP, Brazil

---

**Abstract:** The present study evaluated the position and shape of the mental foramen through Computed Tomography study. A total of 191 examinations of adult male and female toothed patients with an age range of 20 to 60 years were analyzed. The images were obtained through the I-Cat® tomography equipment and later analyzed with the device program itself, on a computer with a Microsoft Windows operating system. The data were organized into frequency tables and a descriptive analysis using the chi-square test, significance level of 5%. There was no statistical difference between genders and sides regarding the position and shape of the mental foramen. The mental foramen observed in this study was more frequently located at apex level in the vertical position and between the premolars in the horizontal position. The oval shape was the most frequent. It is expected that this work has a contribution to the dental surgeon in the knowledge of the form and the correct positioning of the mental foramen making possible a favorable prognosis in his clinical interventions.

**Keywords:** Mental foramen; Cone-Beam Computed Tomography; Anatomy

---

### I. Introduction

The mental foramen (MF) is an anatomical structure that presents as a radiolucent image rounded in the region of the lower premolars and may undergo changes. The mental nerve is a terminal branch of the inferior alveolar nerve that emerges through the MF, providing sensitive innervations to the lower lip, buccal vestibule and gingival tissue to the mesial region of the first lower molar (1).

Advances in surgery, bone graft procedures and surgical techniques in endodontics, besides the introduction of new imaging techniques, have renewed interest in the study of this anatomical structure and its possible variations (2,3).

The location of the MF is of great relevance to many areas of dentistry, which involves its correct identification and location to perform its procedures safely. (1).

Two-dimensional radiographic examinations present limitations in visualization and localization of anatomical structures. Thus, although panoramic radiography is a simple, inexpensive and widely used examination in dentistry, its efficacy for surgical planning in the mandible should be studied (2).

Cone-Beam Computed Tomography (CBCT), in addition to low cost and lower radiation dose comparing to medical tomography, allows a better visualization of anatomical repairs, contributing to decrease risks during surgery, minimizing damage to nerves and blood vessels, and improving the effectiveness of anesthetic blocks (2).

The importance of knowing the location of MF is related to the correct anesthetic blockade, differential diagnosis of bone pathologies, forensic dentistry, preoperative planning for implant placement and surgical treatment of endodontic failure (4,5).

The MF, external opening of the mandibular canal (MC), is located on the lateral surface of the mandible's body, usually close to the roots of the lower premolars. From this foramen emerges the mental nervous vessel, the final branch of the inferior alveolar nerve (6).

Anatomical variations associated with MF are relatively uncommon. Among such variations, the presence of one or more accessory mental foramina has been reported in rare cases. The knowledge of its location in relation to the main MF is of fundamental importance in the prior evaluation of surgical and endodontic procedures (7,8).

Several methods have been used to evaluate MF localization, either by means of anatomic-topographic analyzes, studies on dry jaws, performed on cadavers or during surgical procedures and radiographic analyzes. Previous studies have shown that the location of MF can vary according to ethnicity, which makes it important to know the anatomical characteristics of the local population regarding MF position and morphology (9).

The knowledge of the location of the MF is of great importance, since it emerges a vascular-nervous bundle, to perform certain procedures in dentistry, namely, dental implants, orthognathic surgeries, correction of mandibular fractures, anesthetic blocks, placement of prostheses, among other procedures, thus providing interventions with greater safety and lower risk of complications (9).

In addition, knowledge of the position of this foramen allows the dental surgeon to establish a region more appropriate for the insertion of the needle in the anesthetic blockade of the mental nerve (10).

The use of CBCT in dentistry provides better planning since more precise measures of height, width, thickness and bone quality can be obtained. In addition, the relationships between the potential sites for the installation of implants and noble anatomical structures, especially the maxillary sinus, nasal fosse, mental foramen and MC, can be evaluated with more fidelity (11). Studies have shown that CBCT was considered the best method for the evaluation of the tract in the lingual-lingual direction of the MC (12).

Several imaging modalities have been used to evaluate the course of MC and consequently MF, such as: Panoramic Radiography, Linear Tomography, Computed Tomography and the most recent CBCT (2).

Panoramic radiography is widely used by the dental surgeon. This is the technique that is still being used for implant planning because of the surgeon's ability to visualize the presence or absence of teeth or implants in the maxilla and mandible (13).

The distortion in image size varies from 10 to 30%, being a factor of great clinical significance, because different parts of the same image undergo different amounts of magnification. Vertical measurements are inadequately interpreted due to shortening or stretching of anatomical structures because X-ray bundles are neither perpendicular to the long axis of anatomical structures nor to the plane of the film (13).

Due to the multiple image overlays, this technique becomes inaccurate, distorted, lacking sharpness and details when compared to CBCT. The image is two-dimensional, and most appliances do not provide transverse sections, making it impossible to analyze the maxillaries in the vestibular-lingual direction (14).

Although panoramic radiography is generally the most common choice for preoperative planning, its limitations must be taken into account. MF accessories are rarely observed with conventional radiography techniques because the long axis of an accessory foramen is generally less than 1.5 mm, and it is difficult to recognize this structure (8).

CBCT in general is an extremely useful diagnostic aid in the dental clinic. The 3D reconstruction of facial maxillofacial structures allows the surgeon greater security in the planning and execution of the treatment, since the tomography exams allow better visualization of the cases, especially the surgical ones (15).

With the advent of implants, the precise location of anatomical structures, including MF, has become a major need for implant dentists. Because of this, this specialty is an area that depends on tomography images for clinical success, since the evaluation of bone conditions and the relation between important anatomical structures are only well visualized by the presented tomography plans (15,16).

Placement of implants in the mental region in the vicinity of the premolars requires special attention regarding the horizontal position of the MF, due to the anatomical variation of the inferior alveolar nerve, which can extend to form the incisive nerve canal, with an extension anterior to the MF (14). Because of this, the anterior region of the mandible (between the foramina) was considered a safe area; however, many injuries may occur in this region during surgical procedures (17).

It is worth mentioning that injuries to this nerve cause uncomfortable sensor neural changes to the patient, which can be manifested through paresthesia of the lower lip and the skin of the chin, which may be temporary or permanent (18,19). Mental foramen has been used as a constant reference point in the morphometric analysis of the mandible, due to its stable relationship with the mandibular base (19).

The objective of this study was to evaluate the position and shape of the foramen mental by means of conical beam computed tomography, associating side and gender.

## **II. Materials And Methods**

The research was approved by the Ethics and Research Committee of the São Leopoldo Mandic School, whose protocol approval number 1.214.548. In order to evaluate the position and shape of the mental foramen of the patients of a Brazilian subpopulation, an observational study with a descriptive approach (convenience sample) of data analysis was developed.

We analyzed 191 exams of Brazilian male and female toothed adults with an age range of 20 to 60 years, according to the study by Manhães et al. (21). The images used were obtained between January 2014 and January 2015, and were randomly selected from a database of the archive of the Radiology Department of the São Leopoldo Mandic and CRO Faculties.

## II.1. Inclusion Criteria

Adult Brazilian patients of both genders with ages ranging from 20 to 60 years.

## II.2. Exclusion Criteria

Patients with a history of orthodontic treatment, images in which it was not possible to identify the mental foramen, teeth presenting the first and / or second lower premolars with incomplete rhizogenesis and lesions in the premolar region.

## II.3. Obtaining and evaluating images

The images were obtained using the I-Cat® tomography equipment (Imaging Sciences Kavo, Hatfield, PA, USA), and analyzed with the device program itself, on a computer with a Microsoft Windows operating system by a dental radiology specialist, Previously calibrated by a Master Doctor in Radiology with experience in CT analysis. MF was analyzed taking into account the gender and symmetry and according to a modified classification system proposed by Guedes et al. (4):

## II.4. Horizontal relationship

The horizontal position of the MF was classified into 5 categories: 1. anterior to the long axis of the first lower premolar; 2. in line with the long axis of the first lower premolar; 3. between the long axes of the first and second lower premolars; 4. in line with the long axis of the second lower premolar; 5. posterior to the long axis of the second lower premolar.

## II.5. Vertical relationship

The vertical position of the mental foramen was classified into 3 categories: 1. above the level of the apexes of the first and second lower premolars; 2. at the apex of the first and second lower premolars; 3. below the apex of the first and second lower premolars.

## II.6. Form

Mental foramen had its format classified into 3 categories: 1. round; 2. oval; 3. undefined / irregular.

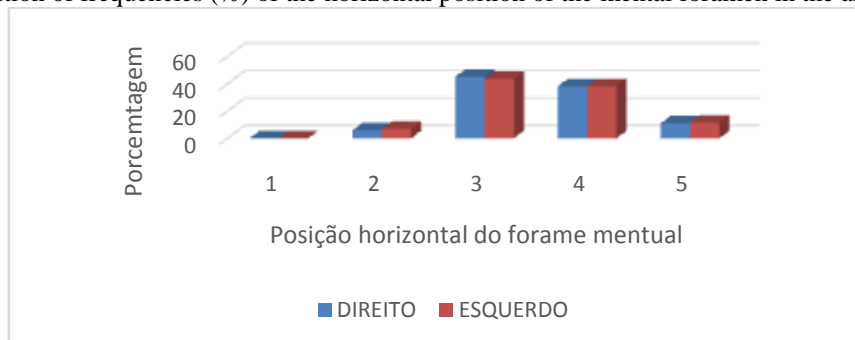
## III. Statistical Analysis

Data were analyzed through frequency distribution tables and Chi-square and Fisher's exact tests, considering a significance level of 5%. We tested the null hypotheses H01: There is no difference between genders regarding the position of the mental foramen; H02: There is no difference between the sides as to the position of the mental foramen; H03: There is no difference between the genders as to the form of the mental foramen; H04: There is no difference between the sides as the form of the mental foramen. All analyzes were performed in the SAS program (SAS Institute Inc., Cary, NC, USA, Release 9.2, 2010).

## IV. Results

It can be observed in figure 1 that there was no significant difference between the genders and between the sides regarding the horizontal position of the mental foramen ( $p > 0.05$ ). The most common positions were "between the long axes of the first and second lower premolars" and "in line with the long axis of the second lower premolar".

Fig 1 - Distribution of frequencies (%) of the horizontal position of the mental foramen in the analyzed sample.

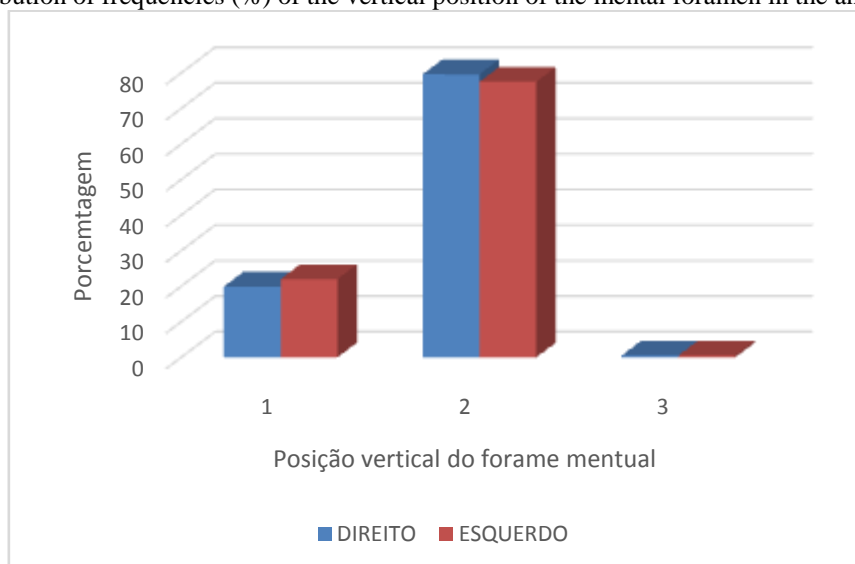


**Legend:** 1. anterior to the long axis of the first lower premolar; 2. in line with the long axis of the first lower premolar; 3. between the long axes of the first and second lower premolars; 4. in line with the long axis of the

second lower premolar; 5. posterior to the long axis of the second lower premolar. P-value (between sides) = 0.9748.

There was also no significant difference between the genders and between the sides regarding the vertical position of the mental foramen ( $p > 0.05$ ), according to Figure 2. The vast majority were in the position "at the apex level of the first and second lower premolars".

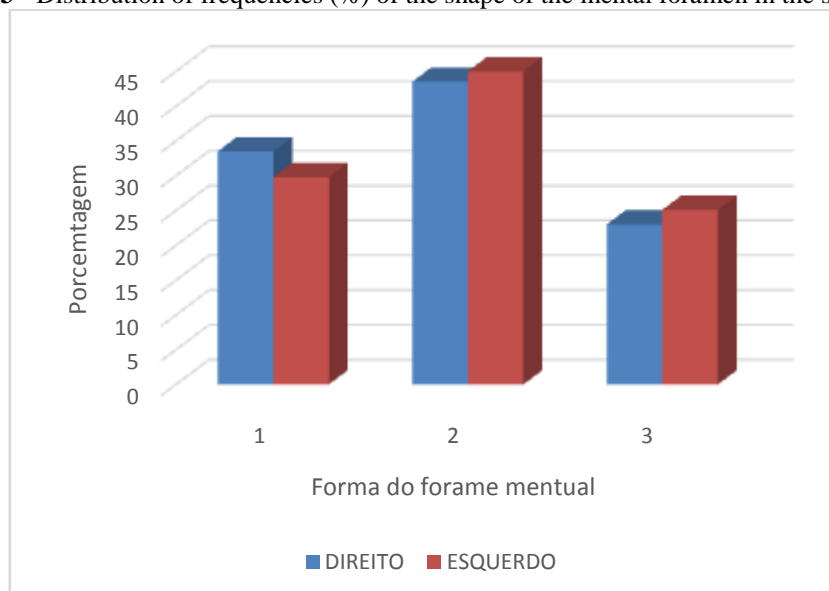
**Fig 2** - Distribution of frequencies (%) of the vertical position of the mental foramen in the analyzed sample.



**Legend:** 1. above the level of the apexes of the first and second lower premolars; 2. at the apex of the first and second lower premolars; 3. below the apex of the first and second lower premolars. P-value (between sides) = 0.8526.

Figure 3 shows a higher frequency of oval, followed by round and undefined / irregular, without significant difference between genders and sides ( $p > 0.05$ ).

**Figure 3** - Distribution of frequencies (%) of the shape of the mental foramen in the sample analyzed.



**Legend:** 1. round; 2. oval; 3. undefined / irregular. P-value (between sides) = 0.7290.

## V. Discussion

The present study used CBCT to study the mental foramen. The choice for this type of image was due to the fact that it allows an accurate visualization of structures that are not visible by conventional radiographic methods.

Moraes et al. (1), Haghanifar & Rokouei (21) and Chkoura & Wady (22) determined the position of the mental foramina in relation to the apexes of the teeth in panoramic radiographs. Chu et al. (23) studied the position of MF in 191 mandibles of Brazilian adults obtained in the Department of Anatomy of the Federal University of São Paulo.

Similarly to the study by Chkoura & Wady (22), we did not find in this work statistically significant difference between genders regarding the position and symmetry of the MF. The most common position, in the horizontal sense, is "between the long axes of the first and second lower premolars". As for Chkoura & Wady (22) and Sheikhi et al. (6) the position was in line with the second premolar. On the other hand, in the study by the researchers Haghanifar & Rokouei (21), 50.9% in females was between the first and second premolars. And in men 49.2% was located in line with the second premolar.

In this study, there was also no significant difference between the genders and between the sides regarding the vertical position of the FM. The vast majority were in the position "at the level of the apexes of the first and second lower premolars". Similarly, in the works of Saito et al. (24) and Sheikhi et al. (6) MF was most frequently located at the apex of the premolars, with a mean distance of 3.1 mm to the lingual cortical, and a mandible base of 7.25 mm on average.

The oval shape followed by the round and later the indefinite / irregular, without significant difference between genders and sides, was the findings of this work. Similarly to the present study, the most common form of MF found by Sheikhi et al. (6) was oval.

When it is a study of anatomical structures, it is worth mentioning that the variation is remarkable for each individual. As a result, more studies should be conducted involving a larger sample and other factors will also be correlated.

## VI. Conclusion

After the data obtained and tabulated it can be concluded that:

**A)** There was no significant difference between genders and sides regarding the position and shape of the MF;

**B)** The position of the MF, as for the horizontal position, the most common were "between the long axes of the first and second lower premolars" and "in line with the long axis of the second lower premolar".

**C)** In the vertical position, the majority was in the position "in level of the apices of the first and second inferior premolars";

**D)** As for the shape of the MF, it was observed a greater frequency of oval form, followed by the round and later indefinite / irregular;

## References

- [1]. Moraes MEL, Manhães Junior LRC, Moraes LC, Medici Filho E, Castilho JCM, Varoli FP, et al. Vertical and horizontal localization of the mental foramen in relation to the second lower premolar by the radiographic method. *RGO, Rev Gaúch Odontol.* 2008; 56 (1): 47-52. 23.
- [2]. Santos CO. Evaluation of the neurovascular anatomy of the mandible by conical beam computed tomography [thesis]. São Paulo: University of São Paulo; 2010.
- [3]. Oliveira HF, Star C, Garrote MS, Zina O, Porto OCL. Radiographic evaluation of the position of the mental foramen in a Brazilian subpopulation [dissertation]. Goiás: Faculty of Dentistry, Federal University of Goiás; 2011.
- [4]. Guedes OA, Rabelo LEG, Porto OCL, Alencar AHG, Estrela C. Radiographic evaluation of the position and shape of the mental foramen in a Brazilian subpopulation. *Rev Odontol Bras Central.* 2011; 20 (53).
- [5]. Saito K, Sousa AC, Lopes VKM, Carvalho PL. Tomographic evaluation of the position of the mental foramen. In: Proceedings of the III Congress of Health Education in the Amazon (COESA), Federal University of Pará, 2014 Nov 12-14; For.
- [6]. Sheikhi M, Kheir MK, Hekmatian E. Cone-beam computed tomography evaluation of mental foramen variations: a preliminary study. *Radiol Res Pract.* 2015; (2015): 1-5.
- [7]. Neves FS, Oliveira LSAF, Torres, MGG, Crusoe-Souza M, Oliveira C, Campos PSF, et al. Accessory mental foramen: case report. *RPG Rev. Pos-grad.* 2010; 17 (3): 173-176.
- [8]. Garay I, Cantín M. mental accessory foramina assessed by cone-beam computed tomography: report of unilateral and bilateral detection. *Int J Morphol.* 2013; 31 (3): 1104-1108.
- [9]. Lima DSC, Figueredo AA, Gravina PR, Mendonça VRR, Castro MP, Chagas GL, et al. Anatomical characterization of the mental foramen in a sample of Brazilian human mandibular jaws. *Rev Bras Cir Craniomaxilofac.* 2010; 13 (4): 230-5.
- [10]. Malamed SF. Manual of local anesthesia. São Paulo: Elsevier; 2005.
- [11]. Nogueira AS, Centurion BS, Fernandes AP, Mendes AC, Cardoso LB, Capelozza ALI. Computed tomography of conical bundle in oral implantology: Report of case series. *Rev Assoc Paul Cir Dent.* 2012; 66 (3): 227-232.
- [12]. Coppédé CT. Study of the prevalence of the vestibular-lingual position of the mandibular canal by helical computerized tomography [dissertation]. São Paulo: University of São Paulo; 2008.
- [13]. Rodrigues GHC, Rodrigues VA, Barros SM, Romeiro RL, Souza DM. Computed tomography x panoramic x-ray in the pre-surgical evaluation in implantology. *Innov Implant J Biomater Esthet.* 2013; 7 (8): 126-131.
- [14]. Shimura MS. Evaluation of the incisive canal of the mandible by means of panoramic radiography and convex beam computed tomography [thesis]. São Paulo: University of São Paulo, 2012.
- [15]. Earth GTC. Evaluation of the accuracy in linear measurements of conical beam computed tomography (CT) and helical computed tomography (CT) examinations performed in human jaw [dissertation]. São Paulo: Ibirapuera University São Paulo; 2011.
- [16]. Sakakura, EC. Diagnostic reproducibility of conventional and inverted digitized panoramic radiographic images in the detection of the canal ceiling of the mandible and the mental foramen [thesis]. Araraquara: State University of São Paulo; 2002.

- [17]. Moura, P. Study of the incidence of anterior extension of the mandibular canal by the computerized tomographic method of conical beam [dissertation]. São José dos Campos: Paulista State University "Júlio de Mesquita Filho"; 2010.
- [18]. Scaf G, Cassano DS, Loffredo LCM. Prevalence of the upper wall of the mandible canal in panoramic radiographs of edentulous patients of both genders. *RevOdontol UNESP*. 2003; 32 (2): 139-43.
- [19]. Amorin, MM. Morphological description of the mandibular canal in panoramic radiographs [dissertation]. Piracicaba: State University of São Paulo; 2006.
- [20]. Manhães Jr LRC, Leonelli de Moraes ME, Cesar de Moraes L, Médici Filho E, Castilho JCM. Classification of the mental foramen and its bilateral correlation. *Rev Odontol*. 2009; 17 (33): 48-53.
- [21]. Haghanifar S, Rokouei M. Radiographic evaluation of the mental foramen in a selected Iranian population. *Indian J Dent Res*. 2009; 20 (2): 150-152.
- [22]. Chkoura A, Wady WE. Position of the mental foramen in a Moroccan population: A radiographic study. *Imaging Sci Dent*. 2013; 43 (2): 71-75.
- [23]. Chu RA, Nahas FX, Di Martino M, Soares FA, Novo NF, Smith RL, et al. The enigma of the mental was as it relates to plastic surgery. *JCraniofac Surg*. 2014; 25 (1): 238-242.
- [24]. Saito K, Araújo NS, Saito MT, Pinheiro JJV, Carvalho PL. Analysis of the mental foramen using cone beam computerized tomography. *Rev Odontol UNESP*. 2015; 44 (4): 226-231.